

Supplementary material for “Exploring the neural correlates of adult outcome of childhood ADHD: A multimodal neuroimaging study of response inhibition.”

fMRI preprocessing

In each of the four stop signal task blocks, a brain mask was automatically created and outliers were computed (any TRs if more than 10% of the voxels in the mask were marked as outliers).

The skull-stripped anatomical MPRAGE scan was aligned to the base volume (i.e., the last TR of the last block). Next, the anatomical scan was aligned to Talairach space using the TT_N27 template. Within each block, all TRs were aligned to the base volume and anatomical scan and transformed to the Talairach template space. Functional data were blurred using a 8mm FWHM Gaussian kernel. Time series in each voxel were scaled to have a mean of 100 (range 0 to 200).

Motion measurements were concatenated across the 4 blocks and the mean of each were removed and their derivatives calculated. Any TRs with > 1 mm in motion parameters were censored. Following the removal of motion-based and voxel outliers, a deconvolution step was performed using 10 different regressors: 6 motion variables and 4 event timing parameters. Each event type (successful and unsuccessful go trials; successful and unsuccessful stop trials) was modeled using a block function lasting 1 s.

MEG data processing

MEG data were analyzed using a combination of MNE-Python(24) and AFNI. The first step was to create Signal Space Projection (SSP) (25) vectors to remove eye blinks and other subject-related artifacts in the raw signal. The data were then visually inspected to rule out any other anomalies. As we were interested in the neural processes underlying inhibition, only inhibit trials

were analyzed further. Each trial was first parsed into individual epochs such that time point 0 marked the onset of the stop signal, and further downsampled to 300Hz.

Cortical reconstruction of anatomical MRI data was performed using the Freesurfer image analysis suite (<http://surfer.nmr.mgh.harvard.edu/>) to create homogenous boundary element models for each subject. Finally, a volumetric source space with 5mm equidistant sources was created for each subject. Data were averaged across trials within condition (successful inhibition, unsuccessful inhibition), and then source-localized using DICS(26) for 5 different frequency bands: delta (1-4Hz), theta (4-8Hz), alpha (8-13Hz), beta (13-30Hz), low gamma (30-55Hz), and high gamma (65-100Hz). The data 500 ms before and after time point 0 were used to construct the noise and data covariance matrices (respectively) that are used by DICS in estimating the power of different sources. Finally, the time course of each source was downsampled to 20Hz, and each subject's image (anatomical + MEG functional: one per band) was morphed into Talairach space.

Robustness analysis fMRI and MEG results

We considered the impact on results of the 9 individuals with ADHD who entered the study as young adults. Of these, 8 provided fMRI data and 5 provided MEG data. We repeated analyses excluding these individuals and found little change in the pattern of results. Specifically: -

ROI analysis results: All ROI results presented in the manuscript held after removing individuals who entered the study as young adults. Specifically, group differences still were present in inferior frontal cortex activation during failed inhibition when contrasted against either successful inhibition (right: $F(2,137)=3.89, p=0.02$; left: $F(2,137)=3.76, p=0.03$), or go trials (left: $F(2,137)=3.87, p=0.02$). The group effects were due to reduced inferior frontal cortex

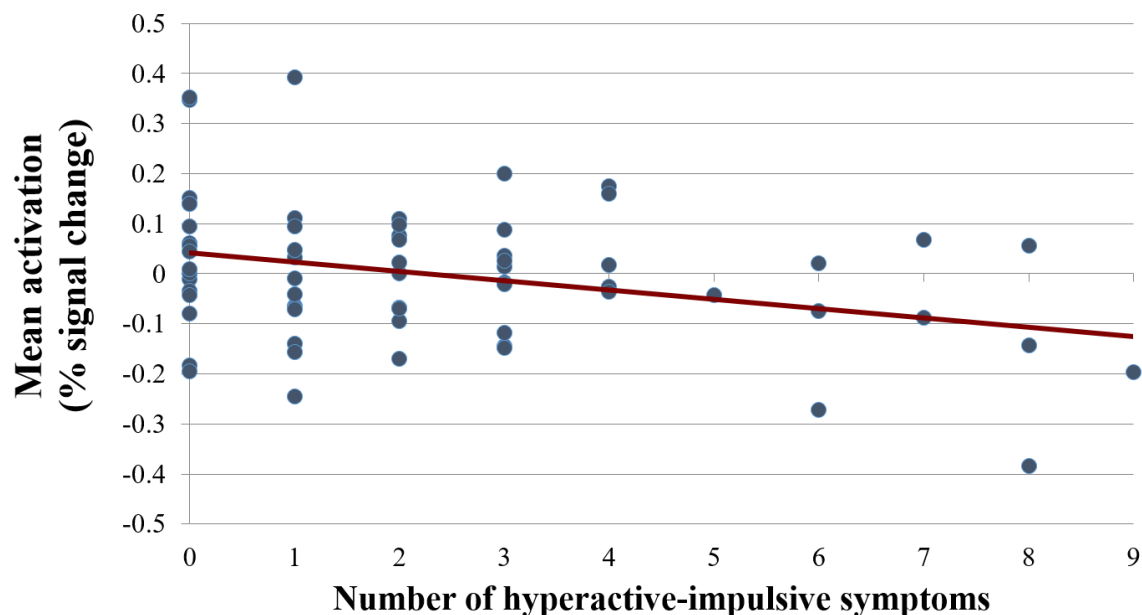
activity during failed inhibition in the persistent group compared to both the remitted group (right: $p=0.007$ (failed vs successful inhibition); left: $p=0.007$ (failed vs successful inhibition) and 0.006 (failed inhibition vs go)) and never-affected individuals (left: $p=0.041$ (failed vs successful inhibition) and 0.033 (failed inhibition vs go)). The remitted and never-affected groups did not differ significantly ($p>0.05$). In symptom-level analyses, higher levels of adult hyperactivity-impulsivity remained significantly associated with decreased activation in the bilateral inferior frontal cortex during failed inhibition contrasted against either successful inhibition (left: $r= -0.30$, $p=0.02$; right: $r= -0.26$, $p=0.05$) or go trials (left: $r= -0.37$, $p=0.005$).

Whole-brain analysis results: The results of whole brain fMRI and MEG presented in the manuscript also largely held after removing participants who entered the study as adults. Specifically, in fMRI we still detected a bilateral cerebellar cluster that showed decreased activation as adult hyperactive-impulsive symptoms increased during successful inhibition contrasted against go trials (1050 voxels, $p<0.05$, cluster-corrected $\alpha<0.001$). The statistical trend for the right inferior parietal result described in the manuscript also held (506 voxels, $p<0.05$, cluster-corrected $\alpha<0.06$).

In MEG, in the three-group ANOVA, the bilateral cerebellar cluster noted in main analyses remained significant in the delta band at 550-600 ms (minimum $F=6.05$, 488 voxels). However the second, left precuneal cluster, though present, did not reach statistical significance. Two of the three results previously reported in the theta band at 500-550 ms after the stop signal during successful inhibition also remained significant (minimum $F=5.25$): the bilateral cerebellar cluster (1165 voxels) and the right inferior parietal cluster (200 voxels). In both frequency bands, the lowest amplitude was observed in the persistent ADHD group and the highest in the never-affected group, with the remitted group showing intermediate levels of activation. Finally, the

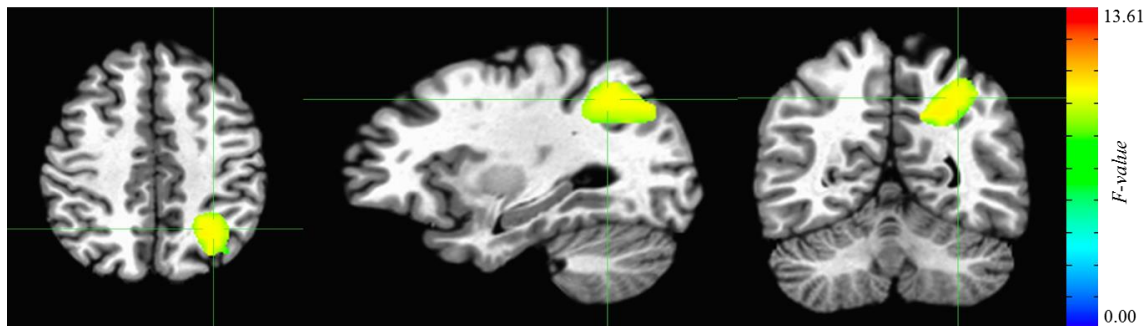
right inferior frontal lobe cluster that was positively associated with hyperactive-impulsive symptoms in the theta band at 300-350 ms during successful inhibition remained significant. The size of the cluster in this robustness analysis was 16 voxels (minimum t -value threshold=4.06, FDR-corrected $p < 0.05$).

Supplemental Figure S1: Correlation ($r = -0.33$, $p = 0.009$) between the number of adult hyperactive-impulsive symptoms and mean activation in the left inferior frontal cortex for the failed inhibition versus go contrast in adults with a childhood history of ADHD. The persistence of more hyperactive-impulsive symptoms in adulthood was associated with lower left inferior frontal cortex activation during failed inhibition.



Supplemental Figure S2: Regions from whole brain MEG analyses where neuronal activity during successful inhibition showed a difference between the three groups (persistent, remitted

and never affected). This group difference was detected in the delta band and emerged at 550-600 ms following the stop signal in the left superior/inferior parietal cluster (69 voxels centered on the left precuneus, MNI coordinates: $x=24.8$, $y=55.8$, $z=36.1$). Compared to the never-affected group, the persistent ADHD group showed under-activation in these regions during successful inhibition. The cerebellar cluster (697 voxels) showing the same group difference in the theta band is shown as Figure 3A in the main manuscript.



Supplemental Figure S3: Regions from whole brain MEG analyses where neuronal activity during successful inhibition showed a difference in the theta band between the three groups. This group difference emerged at 500-550 ms following the stop signal in **A:** Right superior/inferior parietal cluster (341 voxels centered on the right inferior parietal lobe, encompassing areas of the right postcentral gyrus, right cingulate, and right precuneus, MNI coordinates: $x= -35.6$, $y=32.1$, $z=34.9$). **B:** Right inferior parietal/occipital cluster (172 voxels centered on the right cuneus, encompassing areas of the right precuneus, right cingulate gyrus, and right lingual gyrus, MNI coordinates: $x= -11.4$, $y=79.0$, $z=14.7$). The cerebellar region showing the same group difference in the theta band is shown as Figure 3B in the main manuscript.

Figure S3(A)

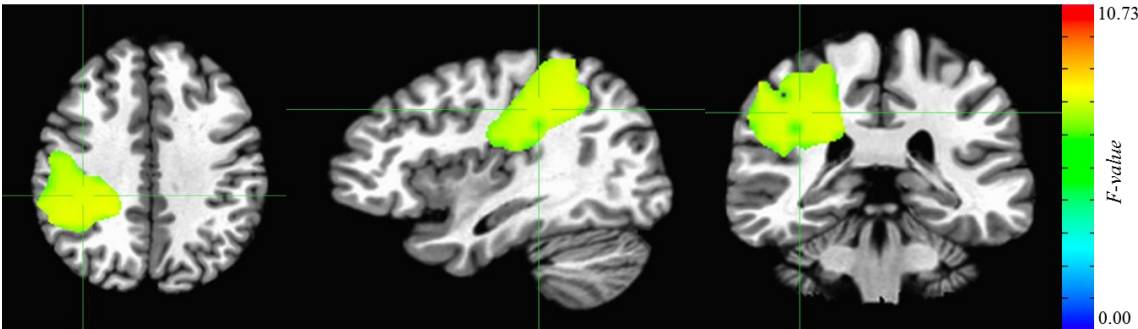


Figure S3(B)

